



# Recommendations for the management of ocular sarcoidosis from the International Workshop on Ocular Sarcoidosis

Hiroshi Takase <sup>1</sup>, Nisha R Acharya,<sup>2</sup> Kalpana Babu,<sup>3</sup> Bahram Bodaghi,<sup>4</sup> Moncef Khairallah,<sup>5</sup> Peter J McCluskey,<sup>6</sup> Nattaporn Tesavibul,<sup>7</sup> Jennifer E Thorne,<sup>8</sup> Ilknur Tugal-Tutkun,<sup>9</sup> Joyce H Yamamoto,<sup>10</sup> Narsing A Rao,<sup>11</sup> 7th IWOS Study Group, Justine R Smith <sup>12</sup>, Manabu Mochizuki<sup>1,13</sup>

► Supplemental material is published online only. To view please visit the journal online (<http://dx.doi.org/10.1136/bjophthalmol-2020-317354>).

For numbered affiliations see end of article.

## Correspondence to

Manabu Mochizuki, Miyata Eye Hospital, 6-3 Kurahara, Miyakonojo 885-0051, Japan; m.manabu.oph@tmd.ac.jp

7th IWOS Study Group: See online supplementary appendix 1. MM and JRS contributed equally to this work and share senior authorship of this manuscript.

Received 5 July 2020  
Revised 15 August 2020  
Accepted 22 August 2020

## ABSTRACT

**Aims** To establish expert recommendations for the management of ocular sarcoidosis (OS).

**Methods** A question-based survey on the management of OS was circulated to international uveitis experts (members of the International Uveitis Study Group and the International Ocular Inflammation Society) electronically. Subsequently, a consensus workshop was conducted at the 7th International Workshop on Ocular Sarcoidosis (IWOS) in June 2019 in Sapporo, Japan as part of the Global Ocular Inflammation Workshops. Statements on the management of OS that were supported by a two-thirds majority of 10 international panel members of the workshop, after discussion and voting, were taken as consensus agreement.

**Results** A total of 98 participants from 29 countries responded to the questionnaire survey. The subsequent consensus workshop established recommendations for the management of OS in five sections. The first section concerned evaluation and monitoring of inflammation. The second, third and fourth sections described ocular manifestations that were indications for treatment, and the management of anterior uveitis, intermediate uveitis and posterior uveitis. In the fifth section, the use of systemic corticosteroids and systemic immunosuppressive drugs were detailed.

**Conclusions** Recommendations for management of OS were formulated through an IWOS consensus workshop.

## INTRODUCTION

Sarcoidosis is a multisystem inflammatory disease of unknown aetiology that is characterised by the presence of noncaseating epithelioid granuloma in the affected organs, including the lung, lymph nodes, skin, liver, heart and eye.<sup>1–3</sup> The eye is one of the most frequently affected organs, and the most common form of ocular sarcoidosis (OS) is uveitis.<sup>4–5</sup> In fact, 30–60% of patients with sarcoidosis develop uveitis, which typically has granulomatous signs, such as mutton fat keratic precipitates (KPs), iris and trabecular meshwork nodules, snowball-like vitreous opacities and multiple chorioretinal peripheral lesions.<sup>6–7</sup>

Uveitis is a sight-threatening disease that affects individuals across the world,<sup>8–10</sup> and previous

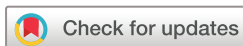studies have reported that uveitis associated with sarcoidosis causes a range of ocular complications, including cataract, glaucoma, cystoid macular oedema and epiretinal membrane, all of which may result in poor visual outcomes.<sup>11–12</sup> Therefore, it is essential to make an accurate diagnosis and initiate appropriate treatment early in the course of the disease. International criteria for the diagnosis of OS were published in 2009 by the International Workshop on Ocular Sarcoidosis (IWOS),<sup>13</sup> and in 2019 the same group reported revised diagnostic criteria.<sup>14</sup> Subsequently, a new consensus IWOS workshop was convened to discuss standard treatments of OS in different regions of the globe and to establish recommendations for the management of OS. The present manuscript reports the results of this workshop.

## METHODS

A consensus workshop—the 7th IWOS—was held on June 29, 2019, during the 2nd Global Ocular Inflammation Workshops in Sapporo, Japan, to discuss and establish recommendations for the management of OS. A two-step process was used to achieve consensus, as outlined below.

### Step 1: a question-based survey

On November 19, 2018, a survey asking about individual experience in the management of OS was circulated electronically to all members of the International Uveitis Study Group (IUSG) and the International Ocular Inflammation Society (IOIS). Uveitis experts at the level of consultant ophthalmologist were invited to complete the survey, and ophthalmic residents and trainee in uveitis were specifically excluded. Those who accepted the invitation were required to respond to the questionnaire by January 31, 2019. The questionnaire survey consisted of five groups of questions which explored: clinical background of respondents (5 questions), management of anterior uveitis (AU, 7 questions), management of intermediate uveitis (IU, 5 questions), management of posterior uveitis (PS, 5 questions) and use of drugs (6 questions). The survey is presented as online supplemental appendix 2. Responses to survey questions that indicated a 70% agreement across international uveitis experts were used to generate recommendations



© Author(s) (or their employer(s)) 2020. No commercial re-use. See rights and permissions. Published by BMJ.

**To cite:** Takase H, Acharya NR, Babu K, *et al.* *Br J Ophthalmol* Epub ahead of print: [please include Day Month Year]. doi:10.1136/bjophthalmol-2020-317354

for the management of OS without further discussion (online supplemental appendix 3).

## Step 2: panel discussion

The moderators of the workshop (MM, JRS and NRA) developed statements for the management of OS based on the results of survey. The statements were presented to 10 international panel members, whose names are given in online supplemental appendix 1. Each statement was discussed by the panel members and statements were revised as necessary, after which the final version of each statement was voted on by the panel members. Only statements with two-thirds majority support by the panel members were identified as consensus agreement for the IWOS recommendations on the management of OS. Based on the discussion and voting on each statement by panel members, recommendations for the management of OS were established.

## RESULTS

### Background of the respondents

Of the IUSG members and IOIS members who were invited to complete the electronic survey, 98 uveitis experts from 29 countries responded. The countries included Australia (3 participants), Austria (2), Bangladesh (1), Belgium (1), Brazil (2), China (1), Czech Republic (1), Ethiopia (1), Germany (3), India (5), Israel (3), Italy (4), Japan (29), Malaysia (2), Mexico (1), Netherlands (3), Philippines (1), Russia (1), Saudi Arabia (1), Serbia (1), Singapore (2), Spain (3), Switzerland (5), Taiwan (4), Thailand (1), Tunisia (1), Turkey (4), UK (3) and USA (9). The annual number of uveitis patients at the respondent's clinic was 100–500 for 42% of the respondents, followed by more than 1000 for 30% and 501–1000 for 23%. The annual load of OS patients was more than 50 patients for 26% of the respondents, followed by 10–30 for 24% and 31–50 for 26%. The clinical background of the respondents is summarised in online supplemental appendix 3.

### Evaluation and monitoring of inflammation

Tools used to evaluate inflammatory activity of OS were optical coherence tomography (OCT) for 95% of respondents, fluorescein angiography for 94%, indocyanine green fluorescein angiography for 44%, flare photometry for 20%, OCT-angiography for 15% and wide view fundus photography for 1%. Use of tools to monitor the effectiveness of therapy was very similar. Based on the survey results and the panel discussion and voting, the panelists recommended that inflammatory activity be evaluated and monitored by clinical examinations and specific ocular imaging tools (see online supplemental appendix 4).

### Therapies for anterior uveitis

Ocular manifestations that are indications for treatment of OS were discussed. All panelists agreed on the following indications for treatment of AU: anterior chamber (AC) cells, new-onset keratic precipitates, iris nodules, angle nodules, new-onset posterior synechia and raised intraocular pressure (IOP) that is not corticosteroid-induced (box 1). For all these indications, the impact on visual acuity must be considered when making the decision to treat.

First-line therapy and second-line therapy for severe and moderate AU were discussed. Here, the definitions of severe and moderate AU were proposed by the moderators, and accepted by all panelists. Severe AU was defined as having AC cells equal to or more than 3+ according to the SUN criteria,<sup>15</sup> new-onset KPs,

and iris nodules, and moderate AU was defined as having AC cells less than 3+. Seven of 10 panelists agreed that first-line therapy for severe AU was instillation of corticosteroid eye drops (prednisolone acetate 1% or equivalent) at least 10 times per day, whereas first-line therapy for moderate AU was instillation of corticosteroid eye drops at least 6 times per day.

All the panelists agreed that second-line therapy for severe AU included subconjunctival dexamethasone injection, periocular triamcinolone acetonide (TA) injection and systemic corticosteroid, and that second-line therapy for moderate AU included more frequent corticosteroid eye drops, subconjunctival dexamethasone injection, periocular TA injection and systemic corticosteroid. Two other questions related to AU management had already achieved more than 70% of agreement by the questionnaire, resulting in statements that indicated inactive AU did not require treatment, and mydriatic eye drops were used when AU was active (box 1).

### Therapies for intermediate uveitis

Concerning the indications for the treatment of IU, all the panelists agreed to include diffuse vitreous opacities, snowball-like vitreous opacities, snowbanks and macular oedema (box 2). For all these indications, the impact on visual acuity must be considered in deciding to treat.

First-line and second-line therapies for bilateral and unilateral IU were discussed. As first-line therapy for active bilateral or unilateral IU, seven of 10 panelists agreed to include local corticosteroid (ie, periocular TA injection, intravitreal injection of TA (IVTA) and corticosteroid implant), and systemic corticosteroid (box 2). As second-line therapy for active bilateral or unilateral IU, all the panelists agreed that this included local corticosteroid (ie, periocular TA injection, IVTA and corticosteroid implant), systemic corticosteroid and non-biologic corticosteroid-sparing systemic immunosuppressive drugs (box 2).

### Therapies for posterior uveitis

The panel members agreed to include macular oedema, optic disc nodules/granulomas, nodular and/or segmental periphlebitis, active chorioretinal peripheral lesions and choroidal nodules as

#### Box 1 Management of anterior uveitis (AU) in ocular sarcoidosis (OS)

1. Ocular manifestations that are indicators for treatment in AU include anterior chamber (AC) cells, new-onset keratic precipitates, iris nodules, angle nodules, new-onset posterior synechia and raised IOP (not corticosteroid-induced).
2. First-line therapy for severe AU (AC cell  $\geq 3+$ , new-onset KPs, iris nodules) is instillation of corticosteroid eye drops (prednisolone acetate 1% or similar) at least 10 times per day.
3. First-line therapy for moderate AU (AC cell  $< 3+$ ) is instillation of corticosteroid eye drops at least 6 times per day.
4. Second-line therapy in severe AU includes subconjunctival dexamethasone injection, periocular triamcinolone acetonide injection and systemic corticosteroid.
5. Second-line therapy for moderate AU includes more frequent corticosteroid eye drops, subconjunctival dexamethasone injection, periocular triamcinolone acetonide injection and systemic corticosteroid.
6. Inactive AU does not require treatment.
7. Mydriatic eye drops are used when AU is active.

**Box 2 Management of intermediate uveitis (IU) in ocular sarcoidosis (OS)**

1. Ocular manifestations that are indicators for treatment in IU include diffuse vitreous opacities, snowball-like vitreous opacities, snowbanks and macular oedema.
2. First-line therapy for active bilateral IU includes local corticosteroid (periocular, intravitreal, implant) and systemic corticosteroid.
3. First-line therapy for active unilateral IU is exactly the same as above.
4. Second-line therapy for active bilateral IU includes local corticosteroid (periocular, intravitreal, implant), systemic corticosteroid, and non-biologic corticosteroid-sparing systemic immunosuppressive drugs.
5. Second-line therapy for active unilateral IU is exactly same as above.

**Box 3 Management of posterior uveitis (PU) in ocular sarcoidosis (OS)**

1. Ocular manifestations that are indicators for treatment in PU include macular oedema, optic disc nodules/granulomas, nodular and/or segmental periphlebitis, active chorioretinal peripheral lesions and choroidal nodules.
2. First-line therapy for active bilateral PU includes systemic corticosteroid alone or with corticosteroid-sparing non-biologic systemic immunosuppressive drugs and local corticosteroid (periocular, intravitreal, implant).
3. First-line therapy for active unilateral PU is exactly the same as above.
4. Second-line therapy for active bilateral PU is same as first-line, with exception that biologic drugs are included.
5. Second-line therapy for active unilateral PU is exactly same as above.

**Box 4 Drugs for the management of ocular sarcoidosis (OS)**

1. Mean initial dose of systemic prednisone/prednisolone is 0.5–1.0 mg/kg/day, to a maximum dose of 80 mg/day.
2. Mean duration of the initial dose of systemic prednisone/prednisolone is 2–4 weeks.
3. The mean duration of total treatment with systemic prednisone/prednisolone is 3–6 months.
4. The initial corticosteroid-sparing immunosuppressive drugs include methotrexate, azathioprine, mycophenolate mofetil and ciclosporin.
5. In selected settings of severe disease, some specialists may consider intravenous pulse corticosteroid.
6. Biologic drugs (adalimumab) are used if necessary.

indications for treatment of PU (box 3). As for the other forms of uveitis, impact on visual acuity must be considered in deciding to treat for these indications.

First-line and second-line therapies for active bilateral and unilateral PU were discussed. All the panelists agreed that first-line therapy for active bilateral or unilateral PU included systemic corticosteroid or local corticosteroid (ie, periocular TA injection, IVTA and corticosteroid implant) alone, or with non-biologic corticosteroid-sparing systemic

immunosuppressive drugs. The second-line therapy for active bilateral and unilateral PU was determined to be the same as first-line, with the exception that biologic drugs were now included as an option for corticosteroid-sparing systemic immunosuppressive drugs (box 3).

**Drugs**

The usage of systemic drugs was discussed. First, initial and maximum dose and duration of systemic corticosteroid were discussed. Seven of 10 panelists agreed to recommend a mean initial dose of prednisone/prednisolone as 0.5–1.0 mg/kg/day, to a maximum dose of 80 mg/day. Eight panelists agreed that the mean duration of this initial prednisone/prednisolone was 2–4 weeks, and nine panelists agreed that the average of total duration of therapy with prednisone/prednisolone was 3–6 months. All 10 panelists agreed that the initial corticosteroid-sparing immunosuppressive drugs included methotrexate, azathioprine, mycophenolate mofetil and ciclosporin. It was noted that for severe disease, some specialists considered pulsed intravenous corticosteroid. Questions regarding the biologics had already achieved more than 70% of agreement on the questionnaire; 74% of respondents answered that they used biologic drugs for OS, specifically adalimumab (100%) of those respondents (box 4).

**DISCUSSION**

Previously, guidelines have been produced for the management of noninfectious uveitis,<sup>16–19</sup> or the use of systemic immunosuppressive drugs for systemic sarcoidosis.<sup>20–21</sup> However, there have been no internationally generated guidelines focusing on management of OS, except for the statement by the American Thoracic Society (ATS), the European Respiratory Society (ERS) and the World Association of Sarcoidosis and Other Granulomatous Disorders (WASOG), which was published over 20 years ago,<sup>22</sup> and Japanese consensus statements for diagnosis and management of OS, which were written in Japanese.<sup>23</sup> In the ATS/ERS/WASOG statement, treatment of the various manifestations of sarcoidosis is generally described, and the treatment of OS is not detailed beyond the use of topical corticosteroid for AU, and systemic therapy for ‘eye disease’ that does not respond to topical therapy.<sup>22</sup> Our project represents the first international collaborative effort to establish recommendations specifically for the management of OS.

The question-based survey was sent to uveitis specialists all over the world through two major international uveitis societies, IOIS and IUSG, and responses were received from uveitis specialists based in 29 countries. Probably because of variation in the incidence and general interest in sarcoidosis in different countries, there were differences in the number of respondents from each country, with many responses from Japan. We recognised that bias might impact the results of the survey, and we addressed potential bias by involving a panel of 10 uveitis specialists from nine different countries.

In designing the questionnaire survey, the authors expected that many of the respondents might choose local corticosteroid therapies for unilateral uveitis instead of systemic treatment, because local corticosteroid therapies are reported to have significant efficacy for noninfectious IU or PU.<sup>24–25</sup> In fact, for the treatment of IU and PU, the 60% of the survey respondents chose oral corticosteroid as the first-line therapy for bilateral disease, while around 50% chose subtenon injection of TA as the first-line therapy for unilateral disease. However, the percentage of those responders did not exceed 70%, and these issues were discussed

by the panel members, resulting in recommendations of the same treatment for bilateral and unilateral IU and PU.

Because these IWOS recommendations are based on expert opinion, they should be validated by an international multicenter prospective study of the treatment of OS. In recent years, effectiveness of different biologic drugs for noninfectious uveitis has been reported.<sup>26 27</sup> These studies included all forms of noninfectious uveitis, and the number of OS patients were limited. Apart from a low incidence, OS is not a uniform disease and shows a variety of ocular manifestations and systemic disease involvements. For the success of a study to validate the IWOS management recommendations, it will be important to recruit patients using the revised IWOS diagnostic criteria.<sup>14</sup>

There are some caveats to this study. One important point relates to the availability of devices and drugs, which differ according to medical care systems and/or health insurance policies in the different parts of the world. In addition, differences in the racial background of the patients are not factored into these recommendations, but should be considered when applying them to patients. Also, although the effectiveness of tumor necrosis factor (TNF) inhibitors has been established for noninfectious uveitis, a paradoxical sarcoidosis-like illness has been reported in patients treated with this class of drugs,<sup>28 29</sup> and awareness of this complication is important when TNF-inhibitors are prescribed to patients with OS. Finally, these recommendations do not refer to the management of complications of OS, such as cataract, glaucoma, cystoid macular edema, and other vitreoretinal disorders that may require surgical intervention and adequate peri-operative control of inflammation. Another future international collaborative study is planned to establish recommendations on this topic.

In conclusion, recommendations for the management of OS by IWOS were formulated based on questionnaire responses of international uveitis experts from 29 countries, and a consensus workshop held by IWOS (online supplemental appendix 4).

#### Author affiliations

<sup>1</sup>Department of Ophthalmology and Visual Science, Graduate School of Medical and Dental Sciences, Tokyo Medical and Dental University, Tokyo, Japan

<sup>2</sup>Proctor Foundation, University of California San Francisco, San Francisco, CA, USA

<sup>3</sup>Prabha Eye Clinic and Research Centre, Vittala International Institute of Ophthalmology, Bangalore, India

<sup>4</sup>Department of Ophthalmology, IHU FORSIGHT, Sorbonne-APHP, Paris, France

<sup>5</sup>Department of Ophthalmology, Fattouma Bourguiba University Hospital, Faculty of Medicine, University of Monastir, Monastir, Tunisia

<sup>6</sup>Save Sight Institute, Discipline of Clinical Ophthalmology and Eye Health, Faculty of Medicine and Health, The University of Sydney, Sydney, NSW, Australia

<sup>7</sup>Department of Ophthalmology, Faculty of Medicine Siriraj Hospital, Mahidol University, Bangkok, Thailand

<sup>8</sup>Division of Ocular Immunology, The Wilmer Eye Institute, The Johns Hopkins University School of Medicine, BaltimoreMD, USA

<sup>9</sup>Department of Ophthalmology, Istanbul Faculty of Medicine, Istanbul University, Istanbul, Turkey

<sup>10</sup>Department of Ophthalmology, Faculdade de Medicina LIM-33 FMUSP, Universidade de Sao Paulo, Sao Paulo, SP, Brazil

<sup>11</sup>USC Roski Eye Institute, Department of Ophthalmology, Keck School of Medicine of University of Southern California, Los Angeles, CA, USA

<sup>12</sup>Flinders University College of Medicine and Public Health, Adelaide, SA, Australia

<sup>13</sup>Miyata Eye Hospital, Miyakonojo, Japan

**Correction notice** This paper has been corrected since it was published online. During the production process the production team failed to include 7th IWOS Study Group in the author list. We would like to apologise for this error.

**Contributors** MM and JRS conceived the project; designed the study; collected the questionnaire survey; designed, conducted and moderated the seventh International Workshop on Ocular Sarcoidosis on June 29, 2019 in Sapporo, Japan. HT, MM and JRS drafted the manuscript. NRA, KB, BB, MK, PJM, NT, JET, ITT, JHY and NAR reviewed and edited the manuscript draft. HT analysed the results of the questionnaire survey. MM, JRS and HT built up questionnaire survey, designed the study and reviewed the questionnaire survey. NAR made suggestions for the study. All authors and members

of International Workshop on Ocular Sarcoidosis Study Group participated in the questionnaire survey and in the seventh International Workshop on Ocular Sarcoidosis on June 29, 2019 in Sapporo, Japan. All authors approved submission.

**Funding** The authors have not declared a specific grant for this research from any funding agency in the public, commercial or not-for-profit sectors.

**Competing interests** None declared.

**Provenance and peer review** Not commissioned; externally peer reviewed.

**Data availability statement** All data relevant to the study are included in the article or uploaded as online supplemental information.

**Supplemental material** This content has been supplied by the author(s). It has not been vetted by BMJ Publishing Group Limited (BMJ) and may not have been peer-reviewed. Any opinions or recommendations discussed are solely those of the author(s) and are not endorsed by BMJ. BMJ disclaims all liability and responsibility arising from any reliance placed on the content. Where the content includes any translated material, BMJ does not warrant the accuracy and reliability of the translations (including but not limited to local regulations, clinical guidelines, terminology, drug names and drug dosages), and is not responsible for any error and/or omissions arising from translation and adaptation or otherwise.

#### ORCID iDs

Hiroshi Takase <http://orcid.org/0000-0001-8327-803X>

Justine R Smith <http://orcid.org/0000-0002-4756-5493>

#### REFERENCES

- Hunninghake GW, Costabel U, Ando M, *et al*. ATS/ERS/WASOG statement on sarcoidosis. American Thoracic Society/European Respiratory Society/World Association of Sarcoidosis and other granulomatous disorders. *Sarcoidosis Vasc Diffuse Lung Dis* 1999;16:149–73.
- Newman LS, Rose CS, Maier LA. Sarcoidosis. *N Engl J Med* 1997;336:1224–34.
- Matsou A, Tsaousis KT. Management of chronic ocular sarcoidosis: challenges and solutions. *Clin Ophthalmol* 2018;12:519–32.
- Ma SP, Rogers SL, Hall AJ, *et al*. Sarcoidosis-related uveitis: clinical presentation, disease course, and rates of systemic disease progression after uveitis diagnosis. *Am J Ophthalmol* 2019;198:30–6.
- Ungerprasert P, Tooley AA, Crowson CS, *et al*. Clinical characteristics of ocular sarcoidosis: a population-based study 1976–2013. *Ocul Immunol Inflamm* 2019;27:389–95.
- Ohara K, Okubo A, Sasaki H, *et al*. Intraocular manifestations of systemic sarcoidosis. *Jpn J Ophthalmol* 1992;36:452–7.
- Jabs DA, Johns CJ. Ocular involvement in chronic sarcoidosis. *Am J Ophthalmol* 1986;102:297–301.
- Suttorp-Schulten MS, Rothova A. The possible impact of uveitis in blindness: a literature survey. *Br J Ophthalmol* 1996;80:844–8.
- Durrani OM, Tehrani NN, Marr JE, *et al*. Degree, duration, and causes of visual loss in uveitis. *Br J Ophthalmol* 2004;88:1159–62.
- de Smet MD, Taylor SR, Bodaghi B, *et al*. Understanding uveitis: the impact of research on visual outcomes. *Prog Retin Eye Res* 2011;30:452–70.
- Rochepeau C, Jamilloux Y, Kerever S, *et al*. Long-term visual and systemic prognoses of 83 cases of biopsy-proven sarcoid uveitis. *Br J Ophthalmol* 2017;101:856–61.
- Coulon C, Kodjikian L, Rochepeau C, *et al*. Ethnicity and association with ocular, systemic manifestations and prognosis in 194 patients with sarcoid uveitis. *Graefes Arch Clin Exp Ophthalmol* 2019;257:2495–503.
- Herbert CP, Rao NA, Mochizuki M. International criteria for the diagnosis of ocular sarcoidosis: results of the first international workshop on ocular sarcoidosis (IWOS). *Ocul Immunol Inflamm* 2009;17:160–9.
- Mochizuki M, Smith JR, Takase H, *et al*. Revised criteria of international workshop on ocular sarcoidosis (IWOS) for the diagnosis of ocular sarcoidosis. *Br J Ophthalmol* 2019;103:1418–22.
- Jabs DA, Nussenblatt RB, Rosenbaum JT, *et al*. Standardization of uveitis nomenclature for reporting clinical data. Results of the first international workshop. *Am J Ophthalmol* 2005;140:509–16.
- Diwo E, Seve P, Trad S, *et al*. Therapeutic strategy for the treatment of non-infectious uveitis proposed by an expert panel. *Rev Med Interne* 2018;39:687–98.
- Espinosa G, Munoz-Fernandez S, Garcia Ruiz de Morales JM, *et al*. Treatment recommendations for non-infectious anterior uveitis. *Med Clin (Barc)* 2017;149:552e1–52 e12.
- Mackensen F, Baydoun L, Garweg J, *et al*. Intermediate uveitis: guidelines of the German Ophthalmological Society and the professional association of German ophthalmologists. *Der Ophthalmologe* 2014;111:1033–40.
- Dick AD, Rosenbaum JT, Al-Dhibi HA, *et al*. Guidance on noncorticosteroid systemic immunomodulatory therapy in noninfectious uveitis: fundamentals of care for uveitis (FOCUS) initiative. *Ophthalmology* 2018;125:757–73.
- Cremer JP, Drent M, Bast A, *et al*. Multinational evidence-based world association of sarcoidosis and other granulomatous disorders recommendations for

- the use of methotrexate in sarcoidosis: integrating systematic literature research and expert opinion of sarcoidologists worldwide. *Curr Opin Pulm Med* 2013;19:545–61.
- 21 Drent M, Cremers JP, Jansen TL, *et al.* Practical eminence and experience-based recommendations for use of TNF-alpha inhibitors in sarcoidosis. *Sarcoidosis Vasc Diffuse Lung Dis* 2014;31:91–107.
  - 22 Statement on Sarcoidosis. Joint statement of the American Thoracic Society (ATS), the European Respiratory Society (ERS) and the World Association of Sarcoidosis and Other Granulomatous disorders (WASOG) adopted by the ATS board of directors and by the ERS executive committee, february 1999. *Am J Respir Crit Care Med* 1999;160:736–55.
  - 23 Consensus statements for the management of sarcoidosis 2018 (in Japanese). Available <https://www.jsog.com/wp/wp-content/themes/jsog/images/system/guidance/2-4-2.pdf>
  - 24 Ferrante P, Ramsey A, Bunce C, *et al.* Clinical trial to compare efficacy and side-effects of injection of posterior sub-Tenon triamcinolone versus orbital floor methylprednisolone in the management of posterior uveitis. *Clin Exp Ophthalmol* 2004;32:563–8.
  - 25 Thorne JE, Sugar EA, Holbrook JT, *et al.* Periocular triamcinolone vs. Intravitreal triamcinolone vs. Intravitreal dexamethasone implant for the treatment of uveitic macular edema: the periocular vs. INTravitreal corticosteroids for uveitic macular edema (POINT) trial. *Ophthalmology* 2019;126:283–95.
  - 26 Letko E, Yeh S, Foster CS, *et al.* Efficacy and safety of intravenous secukinumab in noninfectious uveitis requiring steroid-sparing immunosuppressive therapy. *Ophthalmology* 2015;122:939–48.
  - 27 Jaffe GJ, Dick AD, Brezin AP, *et al.* Adalimumab in patients with active noninfectious uveitis. *N Engl J Med* 2016;375:932–43.
  - 28 Massara A, Cavazzini L, La Corte R, *et al.* Sarcoidosis appearing during anti-tumor necrosis factor alpha therapy: a new “class effect” paradoxical phenomenon. Two case reports and literature review. *Semin Arthritis Rheum* 2010;39:313–9.
  - 29 Tong D, Manolios N, Howe G, *et al.* New onset sarcoid-like granulomatosis developing during anti-TNF therapy: an under-recognised complication. *Intern Med J* 2012;42:89–94.